13

Special Senses: The Eye and Ear

Learning Objectives

Upon completion of this chapter, you will be able to

- Identify and define the combining forms, suffixes, and prefixes introduced in this chapter.
- Correctly spell and pronounce medical terms and major anatomical structures relating to the eye and ear.
- Locate and describe the major structures of the eye and ear and their functions.
- Describe how we see.
- Describe the path of sound vibration.
- Identify and define eye and ear anatomical terms.
- Identify and define selected eye and ear pathology terms.
- Identify and define selected eye and ear diagnostic procedures.
- Identify and define selected eye and ear therapeutic procedures.
- Identify and define selected medications relating to the eye and ear.
- Define selected abbreviations associated with the eye and ear.

Section I: The Eye at a Glance

Function

The eye contains the sensory receptor cells for vision.

Structures

Here are the primary structures that comprise the eye:

choroid
conjunctiva
eye muscles
eyeball
eyelids
lacrimal apparatus
retina
sclera

Word Parts

Here are the most common word parts (with their meanings) used to build eye terms. For a more comprehensive list, refer to the Terminology section of this chapter.

Combining Forms

ambly/o	dull, dim
aque/o	water
blast/o	immature
blephar/o	eyelid
chromat/o	color
conjunctiv/o	conjunctiva
corne/o	cornea
cycl/o	ciliary body
dacry/o	tears
dipl/o	double
emmetr/o	correct, proper
glauc/o	gray
ir/o	iris
irid/o	iris
kerat/o	cornea
lacrim/o	tears
macul/o	macula lutea
mi/o	lessening
mydr/i	widening
nyctal/o	night
ocul/o	eye
ophthalm/o	eye
opt/o	eye, vision
optic/o	eye, vision
papill/o	optic disk
phac/o	lens
phot/o	light
presby/o	old age
pupill/o	pupil
retin/o	retina
scler/o	sclera
stigmat/o	point
uve/o	choroid
vitre/o	glassy

Suffixes

-ician	specialist
-metrist	specialist in measuring
-opia	vision condition
-opsia	vision condition
-phobia	fear
-tropia	turned condition

Prefixes

eso-	inward
exo-	outward
myo-	to shut

The Eye Illustrated

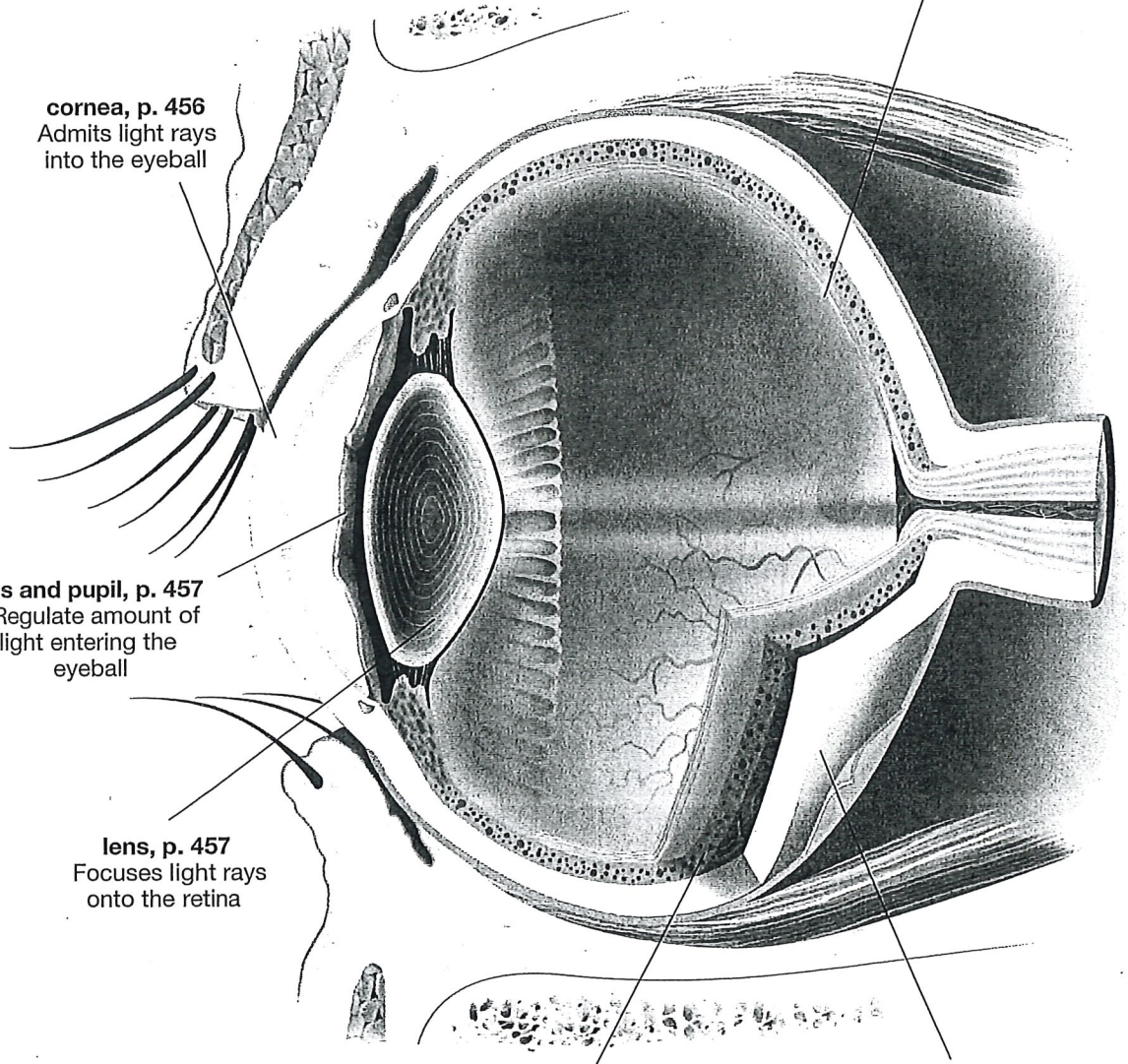

Anatomy and Physiology of the Eye

conjunctiva (kon-JUNK-tih-vah)
eye muscles
eyeball
eyelids
lacrimal apparatus (LAK-rim-al)
ophthalmology (off-thal-MALL-oh-gee)
optic nerve (OP-tik)

Med Term Tip
When studying the functions and terminology of the eye, it is helpful to know the meanings of the terms *opaque* and *transparent.* Opaque means that light is unable to pass through. Transparent, however, means that light is permitted through.

The study of the eye is known as **ophthalmology** (Ophth). The **eyeball** is the incredible organ of sight that transmits an external image by way of the nervous system—the **optic nerve**—to the brain. The brain then translates these sensory impulses into an image with computer-like accuracy.

In addition to the eyeball, several external structures play a role in vision. These are the **eye muscles**, **eyelids**, **conjunctiva**, and **lacrimal apparatus**.

The Eyeball

choroid (KOR-oyd)
retina (RET-in-ah)
sclera (SKLAIR-ah)

The actual eyeball is composed of three layers: the **sclera**, the **choroid**, and the **retina**.

Sclera

cornea (COR-nee-ah)
refracts

Med Term Tip
The color of the sclera may indicate the presence of disease. For instance, a yellowish cast to the sclera can be present in liver disease and certain anemias.

The outer layer, the sclera, provides a tough protective coating for the inner structures of the eye. Another term for the sclera is the "white of the eye."

The anterior portion of the sclera is called the **cornea** (see Figure 13.1 ■). This clear, transparent area of the sclera allows light to enter the interior of the eyeball. The cornea actually bends, or **refracts**, the light rays.

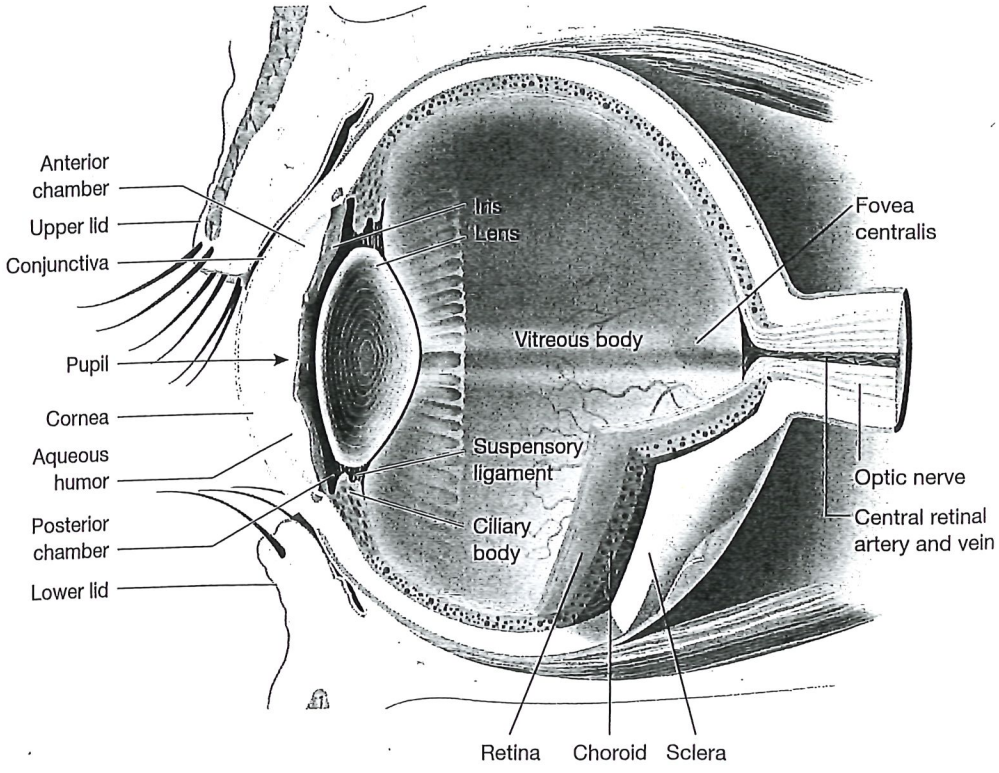

■ **Figure 13.1** The internal structures of the eye.

Choroid

ciliary body (SIL-ee-air-ee)
iris
lens
pupil

The second or middle layer of the eyeball is called the choroid. This opaque layer provides the blood supply for the eye.

The anterior portion of the choroid layer consists of the **iris**, **pupil**, and **ciliary body** (see again Figure 13.1). The iris is the colored portion of the eye and contains smooth muscle. The pupil is the opening in the center of the iris that allows light rays to enter the eyeball. The iris muscles contract or relax to change the size of the pupil, thereby controlling how much light enters the interior of the eyeball. Immediately posterior to the iris is the ciliary body. This is a ring of smooth muscle. Sitting in the center of the ring is the **lens**. The lens is not actually part of the choroid layer, but it is attached to the ciliary body by many thin ligaments called *suspensory ligaments*. The muscular ciliary body contracts or relaxes to pull on the edge of the lens, changing the shape of the lens so it can focus incoming light onto the retina.

Med Term Tip

The function of the choroid, to provide the rest of the eyeball with blood, is responsible for an alternate name for this layer—*uvea*. The combining form *uve/o* means "vascular."

Med Term Tip

The term *ciliary* comes from the Latin word *cilium*, which is taken to refer to the eyelashes (or hair-like structures). In this case, the ciliary body received its name because of the many, very fine ligaments extending from it and attaching to the edge of the lens.

Retina

aqueous humor (AY-kwee-us)
cones
fovea centralis (FOH-vee-ah / sen-TRAH-lis)
macula lutea (MAK-yoo-lah / loo-TEE-ah)
optic disk
retinal blood vessels (RET-in-al)
rods
vitreous humor (VIT-ree-us)

What's In A Name?

aque/o = water
centr/o = center
vitre/o = glassy
-ous = pertaining to

The third and innermost layer of the eyeball is the retina. It contains the sensory receptor cells (**rods** and **cones**) that respond to light rays. Rods are active in dim light and help us to see in gray tones. Cones are active only in bright light and are responsible for color vision. When someone looks directly at an object, the image falls on an area called the **macula lutea**, or "yellow spot" (see again Figure 13.1). In the center of the macula lutea is a depression called the **fovea centralis**, meaning "central pit." This pit contains a high concentration of sensory receptor cells and, therefore, is the point of clearest vision. Also visible on the retina is the **optic disk**. This is the point where the **retinal blood vessels** enter and exit the eyeball and where the optic nerve leaves the eyeball (see Figure 13.2■). There are no sensory receptor cells in the optic disk and therefore it causes a blind spot in each eye's field of vision. The interior spaces of the eyeball are not empty. The spaces between the cornea and lens are filled with **aqueous humor**, a watery fluid, and the large open area between the lens and retina contains **vitreous humor**, a semisolid gel.

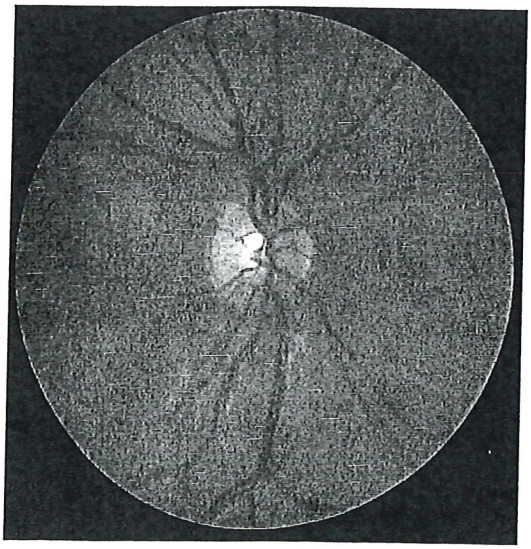

■ **Figure 13.2** Photograph of the retina of the eye. The optic disk appears yellow and the retinal arteries radiate out from it. *(Science Source)*

Muscles of the Eye

oblique muscles (oh-BLEEK) **rectus muscles** (REK-tus)

Med Term Tip

Like many other muscles, the names *rectus* and *oblique* provide clues regarding the direction of their fibers, or their *line of pull.* Rectus means straight and oblique means slanted. Rectus muscles have a straight line of pull. Since the fibers of an oblique muscle are slanted on an angle, they produce rotation.

Six muscles connect the actual eyeball to the skull (see Figure 13.3 ■). These muscles allow for change in the direction of each eye's sightline. In addition, they provide support for the eyeball in the eye socket. Children may be born with a weakness in some of these muscles and may require treatments such as eye exercises or even surgery to correct this problem, commonly referred to as crossed eyes or *strabismus* (see Figure 13.4 ■). The muscles involved are the four **rectus** and two **oblique muscles.** Rectus (meaning "straight") muscles pull the eye up, down, left, or right in a straight line. Oblique muscles are on an angle and produce diagonal eye movement.

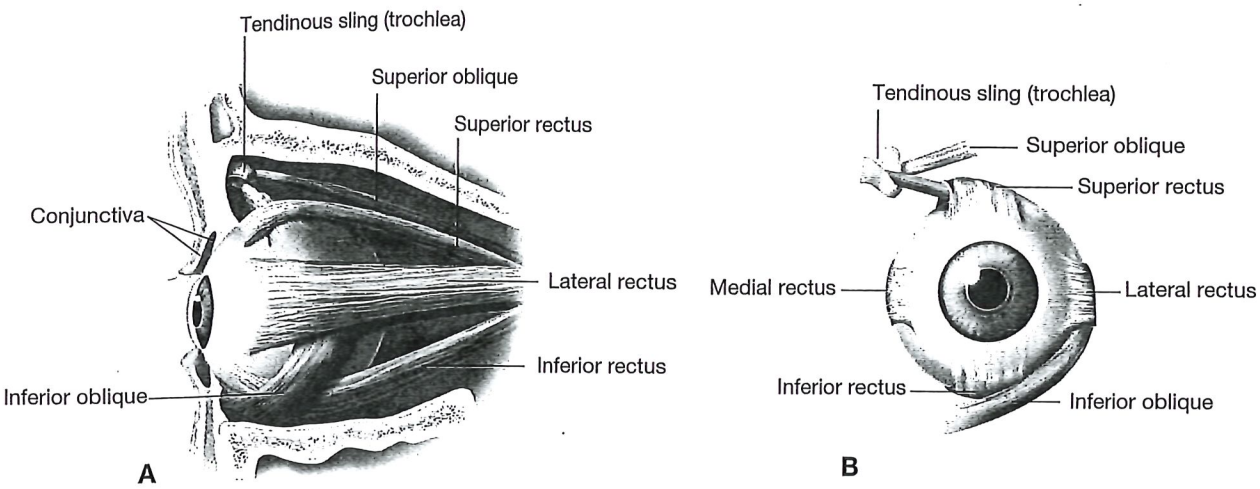

■ **Figure 13.3** The arrangement of the external eye muscles, A) lateral and B) anterior views.

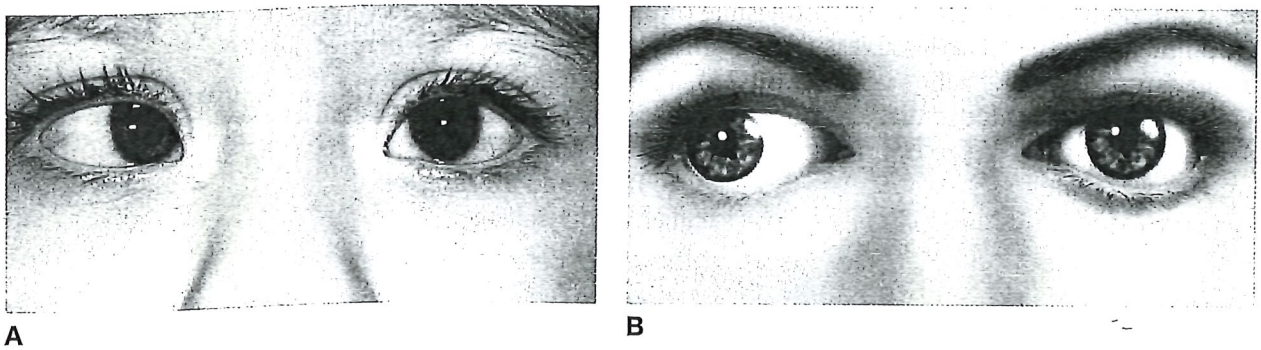

■ **Figure 13.4** Examples of common forms of strabismus. A) Esotropia with the right eye turning inward. *(Biophoto Associates/Science Source)* B) Exotropia with the right eye turning outward. *(Gwen Shockey/Science Source)*

The Eyelids

cilia (SIL-ee-ah) **sebaceous glands** (see-BAY-shus)
eyelashes

What's In A Name?
seb/o = oil
-ous = pertaining to

A pair of eyelids over each eyeball provides protection from foreign particles, injury from the sun and intense light, and trauma (see again Figure 13.1). Both the upper and lower edges of the eyelids have **eyelashes,** or **cilia,** that protect the eye from foreign particles. In addition, **sebaceous glands** located in the eyelids secrete lubricating oil onto the eyeball.

Conjunctiva

mucous membrane

The conjunctiva of the eye is a **mucous membrane** lining. It forms a continuous covering on the underside of each eyelid and across the anterior surface of each eyeball (see again Figure 13.1). This serves as protection for the eye by sealing off the eyeball in the socket.

What's In A Name?
muc/o = mucus
-ous = pertaining to

Lacrimal Apparatus

lacrimal ducts
lacrimal gland
nasal cavity
nasolacrimal duct (naz-oh-LAK-rim-al)
tears

The **lacrimal gland** is located under the outer upper corner of each eyelid. These glands produce **tears**. Tears serve the important function of washing and lubricating the anterior surface of the eyeball. **Lacrimal ducts**, located in the inner corner of the eye socket, then collect the tears and drain them into the **nasolacrimal duct**. This duct ultimately drains the tears into the **nasal cavity** (see Figure 13.5■).

What's In A Name?
lacrim/o = tears
nas/o = nose
-al = pertaining to

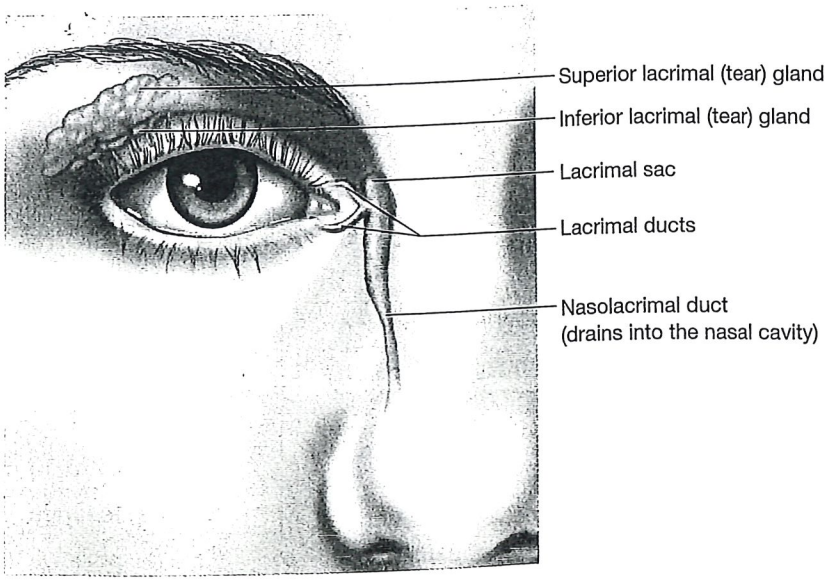

■ **Figure 13.5** The structure of the lacrimal apparatus.

How We See

When light rays strike the eye, they first pass through the cornea, pupil, aqueous humor, lens, and vitreous humor (see Figure 13.6■). They then strike the retina and stimulate the rods and cones. When the light rays hit the retina, an upside-down image is sent along nerve impulses to the optic nerve (see Figure 13.7■). The optic nerve transmits these impulses to the brain, where the upside-down image is translated into the right-side-up image we are looking at.

Vision requires proper functioning of four mechanisms:

1. Coordination of the external eye muscles so that both eyes move together.
2. The correct amount of light admitted by the pupil.
3. The correct focus of light on the retina by the lens.
4. The optic nerve transmitting sensory images to the brain.

■ **Figure 13.6** The path of light through the cornea, iris, lens, and striking the retina.

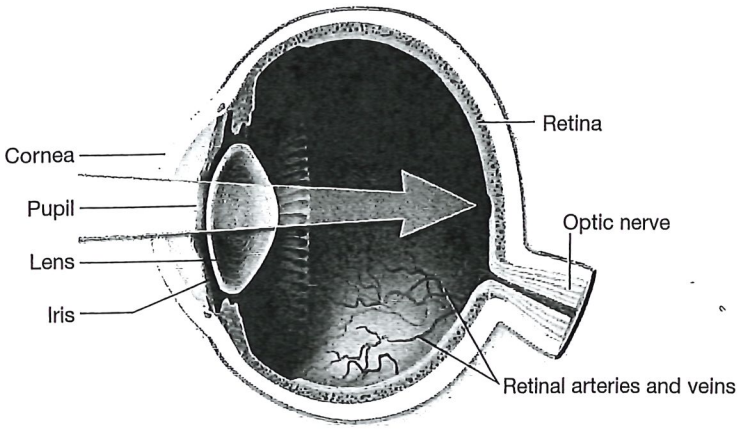

■ **Figure 13.7** The image formed on the retina is inverted. The brain rights the image as part of the interpretation process.

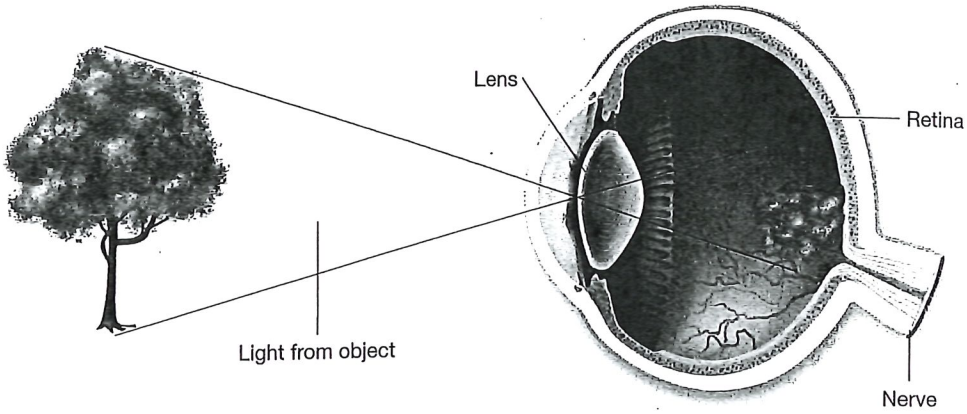

Practice As You Go

A. Complete the Statement

1. The study of the eye is _____.
2. Another term for eyelashes is _____.
3. The glands responsible for tears are called _____ glands.
4. The clear, transparent portion of the sclera is called the _____.
5. The innermost layer of the eye, which is composed of sensory receptors, is the _____.
6. The pupil of the eye is actually a hole in the _____.

Terminology

Word Parts Used to Build Eye Terms

following lists contain the combining forms, suffixes, and prefixes used to build terms in the remaining sections of this chapter.

Combining Forms

aden/o	gland
ambly/o	dull, dim
angi/o	vessel
bi/o	life
blast/o	immature
blephar/o	eyelid
chromat/o	color
conjunctiv/o	conjunctiva
corne/o	cornea
cry/o	cold
cycl/o	ciliary body
cyst/o	sac
dacry/o	tears
dipl/o	double

emmetr/o	correct, proper
esthesi/o	sensation, feeling
glauc/o	gray
ir/o	iris
irid/o	iris
kerat/o	cornea
lacrim/o	tears
macul/o	macula lutea
mi/o	lessening
myc/o	fungus
mydr/i	widening
nyctal/o	night
ocul/o	eye
ophthalm/o	eye

opt/o	eye, vision
optic/o	eye, vision
papill/o	optic disk
phac/o	lens
phot/o	light
presby/o	old age
pupill/o	pupil
retin/o	retina
scler/o	sclera
stigmat/o	point
ton/o	tone
uve/o	choroid
xer/o	dry

Suffixes

-al	pertaining to
-algia	pain
-ar	pertaining to
-ary	pertaining to
-atic	pertaining to
-ectomy	surgical removal
-edema	swelling
-graphy	process of recording
-ia	condition
-ic	pertaining to
-ician	specialist
-ism	state of
-itis	inflammation
-logist	one who studies

-logy	study of
-malacia	abnormal softening
-meter	instrument to measure
-metrist	specialist in measuring
-metry	process of measuring
-oma	tumor; mass
-opia	vision condition
-opsia	vision condition
-osis	abnormal condition
-otomy	cutting into
-pathy	disease

-pexy	surgical fixation
-phobia	fear
-plasty	surgical repair
-plegia	paralysis
-ptosis	drooping
-rrhagia	abnormal flow condition
-scope	instrument for viewing
-scopy	process of visually examining
-tic	pertaining to
-tropia	turned condition

Prefixes

a-	without
an-	without
anti-	against
de-	without
eso-	inward

exo-	outward
extra-	outside of
hemi-	half
hyper-	excessive
intra-	within

micro-	small
mono-	one
myo-	to shut

Adjective Forms of Anatomical Terms

Term	Word Parts	Definition
conjunctival (kon-JUNK-tih-vall)	conjunctiv/o = conjunctiva -al = pertaining to	Pertaining to the conjunctiva.
corneal (KOR-nee-all)	corne/o = cornea -al = pertaining to **Word Watch** Be careful using the combining forms *core/o* meaning "pupil" and *corne/o* meaning "cornea."	Pertaining to the cornea.
extraocular (EKS-truh-OCK-yoo-lar)	extra- = outside of ocul/o = eye -ar = pertaining to	Pertaining to being outside the eyeball; for example, the extraocular eye muscles.
intraocular (in-trah-OCK-yoo-lar)	intra- = within ocul/o = eye -ar = pertaining to	Pertaining to within the eye.
iridal (ir-id-al)	irid/o = iris -al = pertaining to	Pertaining to the iris.
lacrimal (LAK-rim-al)	lacrim/o = tears -al = pertaining to	Pertaining to tears.
macular (MACK-yoo-lar)	macul/o = macula lutea -ar = pertaining to	Pertaining to the macula lutea.
ocular (OCK-yoo-lar)	ocul/o = eye -ar = pertaining to	Pertaining to the eye.
ophthalmic (off-THAL-mik)	ophthalm/o = eye -ic = pertaining to	Pertaining to the eye.
optic (OP-tik)	opt/o = eye, vision -ic = pertaining to	Pertaining to the eye or vision.
optical (OP-tih-kal)	optic/o = eye, vision -al = pertaining to	Pertaining to the eye or vision.
pupillary (PYOO-pih-lair-ee)	pupill/o = pupil -ary = pertaining to	Pertaining to the pupil.
retinal (RET-in-al)	retin/o = retina -al = pertaining to	Pertaining to the retina.
scleral (SKLAIR-all)	scler/o = sclera -al = pertaining to	Pertaining to the sclera.
uveal (YOO-vee-al)	uve/o = choroid -al = pertaining to	Pertaining to the choroid layer of the eye.

Practice As You Go

B. Give the adjective form for each anatomical structure

1. The pupil _____
2. The eye or vision _____ or _____
3. The retina _____
4. Tears _____
5. Within the eye _____
6. Outside of the eye _____

Pathology

Term	Word Parts	Definition
Medical Specialties		
ophthalmologist (opf-thal-MOLL-oh-jist)	ophthalm/o = eye -logist = one who studies	Medical doctor who has specialized in the diagnosis and treatment of eye conditions and diseases.
ophthalmology (Ophth.) (opf-thal-MOLL-oh-jee)	ophthalm/o = eye -logy = study of	Branch of medicine involving the diagnosis and treatment of conditions and diseases of the eye and surrounding structures.
optician (op-TISH-an)	opt/o = vision -ician = specialist	Person trained in grinding and fitting corrective lenses.
optometrist (op-TOM-eh-trist)	opt/o = vision -metrist = specialist in measuring	Doctor of optometry.
optometry (op-TOM-eh-tree)	opt/o = vision -metry = process of measuring	Medical profession specializing in examining the eyes, testing visual acuity, and prescribing corrective lenses.
Signs and Symptoms		
blepharoptosis (blef-ah-rop-TOH-sis)	blephar/o = eyelid -ptosis = drooping	Drooping eyelid.
cycloplegia (sigh-kloh-PLEE-jee-ah)	cycl/o = ciliary body -plegia = paralysis	Paralysis of the ciliary body. This affects changing the shape of the lens to bring images into focus.
diplopia (dip-LOH-pee-ah)	dipl/o = double -opia = vision condition	Condition of seeing double.
emmetropia (EM) (em-eh-TROH-pee-ah)	emmetr/o = correct, proper -opia = vision condition	State of normal vision.
iridoplegia (ir-id-oh-PLEE-jee-ah)	irid/o = iris -plegia = paralysis	Paralysis of the iris. This affects changing the size of the pupil to regulate the amount of light entering the eye.

Pathology (continued)

Term	Word Parts	Definition
nyctalopia (nik-tah-LOH-pee-ah)	**nyctal/o** = night **-opia** = vision condition	Difficulty seeing in dim light; also called *night blindness.* Usually due to damaged rods.
	Med Term Tip The simple translation of *nyctalopia* is "night vision." However, it is used to mean "night blindness."	
ophthalmalgia (off-thal-MAL-jee-ah)	**ophthalm/o** = eye **-algia** = pain	Eye pain.
ophthalmoplegia (off-thal-moh-PLEE-jee-ah)	**ophthalm/o** = eye **-plegia** = paralysis	Paralysis of one or more of the extraocular eye muscles.
ophthalmorrhagia (off-thal-moh-RAH-jee-ah)	**ophthalm/o** = eye **-rrhagia** = abnormal flow condition	Bleeding from the eye.
papilledema (pah-pill-eh-DEEM-ah)	**papill/o** = optic disk **-edema** = swelling	Swelling of the optic disk. Often as a result of increased intraocular pressure. Also called *choked disk.*
photophobia (foh-toh-FOH-bee-ah)	**phot/o** = light **-phobia** = fear	Although the term translates into *fear of light*, it actually means a strong sensitivity to bright light.
presbyopia (prez-bee-OH-pee-ah)	**presby/o** = old age **-opia** = vision condition	Visual loss due to old age, resulting in difficulty in focusing for near vision (such as reading).
scleromalacia (sklair-oh-mah-LAY-she-ah)	**scler/o** = sclera **-malacia** = abnormal softening	Softening of the sclera.
xerophthalmia (zeer-of-THAL-mee-ah)	**xer/o** = dry **ophthalm/o** = eye **-ia** = condition	Dry eyes.
Eyeball		
achromatopsia (ah-kroh-mah-TOP-see-ah)	**a-** = without **chromat/o** = color **-opsia** = vision condition	Severe, congenital deficiency in color vision; complete color blidness; more common in males.
amblyopia (am-blee-OH-pee-ah)	**ambly/o** = dull, dim **-opia** = vision condition	Loss of vision not as a result of eye pathology. Usually occurs in patients who see two images. In order to see only one image, the brain will no longer recognize the image being sent to it by one of the eyes. May occur if strabismus is not corrected. This condition is not treatable with a prescription lens. Commonly referred to as *lazy eye.*
astigmatism (Astigm) (ah-STIG-mah-tizm)	**a-** = without **stigmat/o** = point **-ism** = state of	Condition in which light rays are focused unevenly on the retina, causing a distorted image, due to an abnormal curvature of the cornea.

Pathology (continued)

Term	Word Parts	Definition
cataract (KAT-ah-rakt)	**Med Term Tip** The term *cataract* comes from the Latin word meaning "waterfall." This refers to how a person with a cataract sees the world—as if looking through a waterfall.	Damage to the lens causing it to become opaque or cloudy, resulting in diminished vision. Treatment is usually surgical removal of the cataract or replacement of the lens.
corneal abrasion	**corne/o** = cornea **-al** = pertaining to	Scraping injury to the cornea. If it does not heal, it may develop into an ulcer.
glaucoma (glau-KOH-mah)	**glauc/o** = gray **-oma** = mass	Increase in intraocular pressure, which, if untreated, may result in atrophy (wasting away) of the optic nerve and blindness. Glaucoma is treated with medication and surgery. There is an increased risk of developing glaucoma in persons over age 60, those of African ancestry, people who have sustained a serious eye injury, or anyone with a family history of diabetes or glaucoma.
hyperopia (high-per-OH-pee-ah)	**hyper-** = excessive **-opia** = vision condition	With this condition a person can see things in the distance but has trouble reading material at close range. Also known as *farsightedness.* This condition is corrected with converging or biconvex lenses.

Figure 13.8 Photograph of a person with a cataract in the right eye. *(ARZTSAMUI/Shutterstock)*

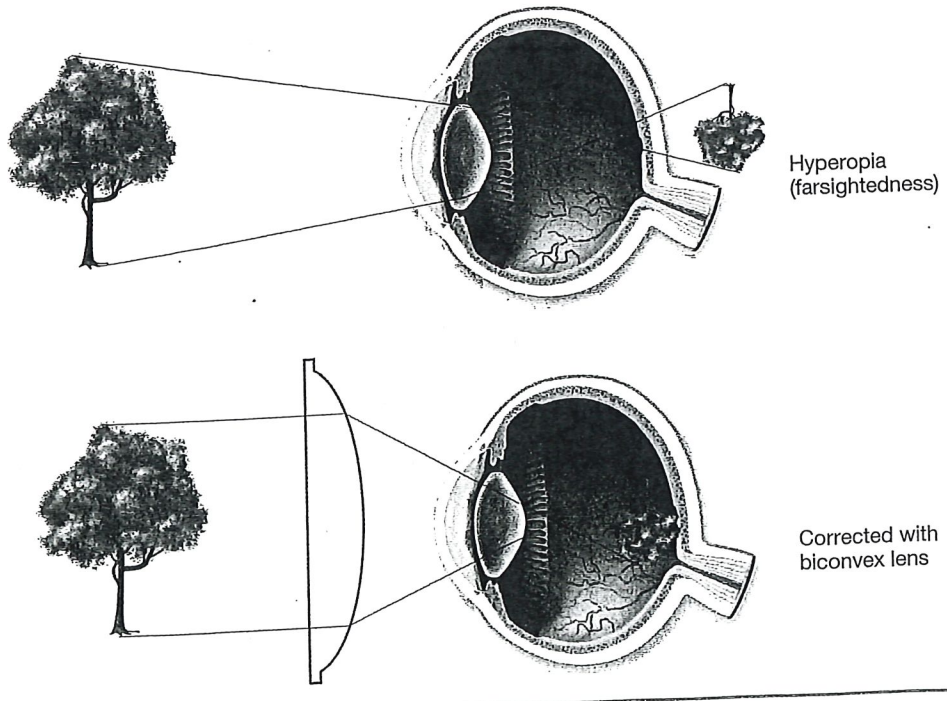

Figure 13.9 Hyperopia (farsightedness). In the uncorrected top figure, the image would come into focus behind the retina, making the image on the retina blurry. The bottom image shows how a biconvex lens corrects this condition.

Pathology (continued)

Term	Word Parts	Definition
iritis (eye-RYE-tis)	**ir/o** = iris **-itis** = inflammation	Inflammation of the iris.
keratitis (kair-ah-TYE-tis)	**kerat/o** = cornea **-itis** = inflammation **Word Watch** Be careful using the combining form *kerat/o*, which means both "cornea" and the "hard protein keratin."	Inflammation of the cornea.
legally blind		Describes a person who has severely impaired vision. Usually defined as having visual acuity of 20/200 that cannot be improved with corrective lenses or having a visual field of less than 20 degrees.
macular degeneration (MAK-yoo-lar)	**macul/o** = macula lutea **-ar** = pertaining to	Deterioration of the macular area of the retina of the eye. May be treated with laser surgery to destroy the blood vessels beneath the macula.
monochromatism (mon-oh-KROH-mah-tizm)	**mono-** = one **chromat/o** = color **-ism** = state of	Unable to perceive one color.
myopia (MY) (my-OH-pee-ah) **Med Term Tip** The term *myopia* appears to use the combining form my/o, which means "muscle." This combining form comes from the Greek word *mys*. But in this case the term uses the prefix myo-, which comes from the Greek word *myo* or *myein*, meaning "to shut."	**myo-** = to shut **-opia** = vision condition	With this condition a person can see things close up but distance vision is blurred. Also known as *nearsightedness.* This condition is corrected with diverging or biconcave lenses. Named because persons with myopia often partially shut their eyes, squint, in order to see better.
oculomycosis (ock-yoo-loh-my-KOH-sis)	**ocul/o** = eye **myc/o** = fungus **-osis** = abnormal condition	Fungus infection of the eye.

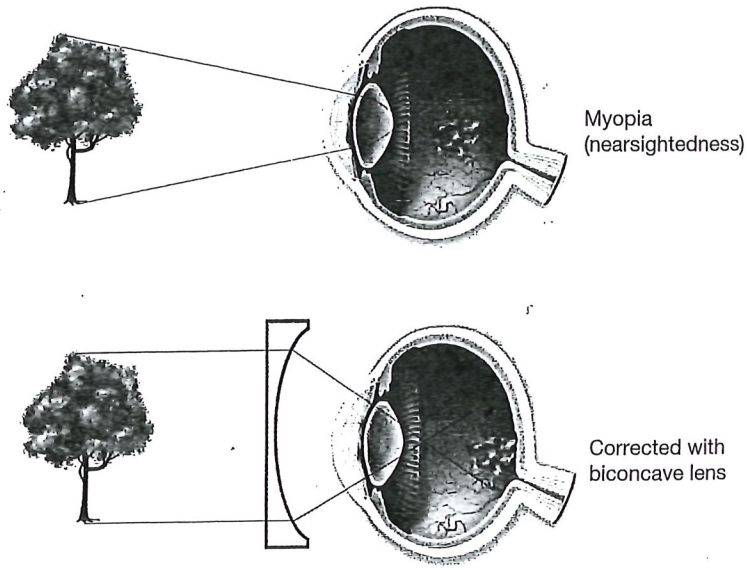

■ **Figure 13.10** Myopia (nearsightedness). In the uncorrected top figure, the image comes into focus in front of the lens, making the image on the retina blurry. The bottom image shows how a biconcave lens corrects this condition.

Pathology (continued)

Term	Word Parts	Definition
retinal detachment (RET-in-al)	retin/o = retina -al = pertaining to	Occurs when the retina becomes separated from the choroid layer. This separation seriously damages blood vessels and nerves, resulting in blindness. May be treated with surgical or medical procedures to stabilize the retina and prevent separation.
retinitis pigmentosa (ret-in-EYE-tis / pig-men-TOH-sah)	retin/o = retina -itis = inflammation	Progressive disease of the eye resulting in the retina becoming hard (sclerosed), pigmented (colored), and atrophied (wasting away). There is no known cure for this condition.
retinoblastoma (RET-in-noh-blast-OH-mah)	retin/o = retina blast/o = immature -oma = tumor	Malignant eye tumor occurring in children, usually under the age of 3. Requires enucleation.
retinopathy (ret-in-OP-ah-thee)	retin/o = retina -pathy = disease	General term for disease affecting the retina.
scleritis (skler-EYE-tis)	scler/o = sclera -itis = inflammation	Inflammation of the sclera.
uveitis (yoo-vee-EYE-tis)	uve/o = choroid -itis = inflammation	Inflammation of the choroid layer.
Conjunctiva		
conjunctivitis (kon-junk-tih-VYE-tis)	conjunctiv/o = conjunctiva -itis = inflammation	Inflammation of the conjunctiva usually as the result of a bacterial infection. Commonly called *pinkeye*.
pterygium (teh-RIJ-ee-um)		Hypertrophied conjunctival tissue in the inner corner of the eye.
Eyelids		
blepharitis (blef-ah-RYE-tis)	blephar/o = eyelid -itis = inflammation	Inflammation of the eyelid.
hordeolum (hor-DEE-oh-lum)		Refers to a *stye* (or *sty*), a small purulent inflammatory infection of a sebaceous gland of the eyelid; treated with hot compresses and/or surgical incision.
Lacrimal Apparatus		
dacryoadenitis (dak-ree-oh-ad-eh-NYE-tis)	dacry/o = tears aden/o = gland -itis = inflammation	Inflammation of the lacrimal gland.
dacryocystitis (dak-ree-oh-sis-TYE-tis)	dacry/o = tears cyst/o = sac -itis = inflammation	Inflammation of the lacrimal sac.
Eye Muscles		
esotropia (ST) (ess-oh-TROH-pee-ah)	eso- = inward -tropia = turned condition	Inward turning of the eye; also called *cross-eyed.* An example of a form of strabismus (muscle weakness of the eye).
exotropia (XT) (eks-oh-TROH-pee-ah)	exo- = outward -tropia = turned condition	Outward turning of the eye; also called *wall-eyed.* Also an example of strabismus (muscle weakness of the eye).

Pathology (continued)		
Term	**Word Parts**	**Definition**
strabismus (strah-BIZ-mus)		Eye muscle weakness commonly seen in children resulting in the eyes looking in different directions at the same time. May be corrected with glasses, eye exercises, and/or surgery.
Brain-Related Vision Pathologies		
hemianopia (hem-ee-ah-NOP-ee-ah)	hemi- = half an- = without -opia = vision condition	Loss of vision in half of the visual field. A stroke patient may suffer from this disorder.
nystagmus (niss-TAG-mus)		Jerky-appearing involuntary eye movements, usually left and right. Often an indication of brain injury.

Practice As You Go

C. Terminology Matching

Match each term to its definition.

1.	_____ emmetropia	a.	opacity of the lens
2.	_____ hyperopia	b.	a form of strabismus
3.	_____ cataract	c.	nearsightedness
4.	_____ astigmatism	d.	due to abnormal curvature of cornea
5.	_____ esotropia	e.	lazy eye
6.	_____ xerophthalmia	f.	involuntary movements of the eye
7.	_____ myopia	g.	farsightedness
8.	_____ nystagmus	h.	normal vision
9.	_____ amblyopia	i.	dry eyes
10.	_____ presbyopia	j.	old-age vision loss

Diagnostic Procedures

Term	Word Parts	Definition
Eye Examination Tests		
color vision tests	 ■ **Figure 13.11** An example of color blindness test. A person with red-green color blindness would not be able to distinguish the green 27 from the surrounding red circles.	Use of polychromic (multicolored) charts to determine the ability of the patient to recognize color.
fluorescein angiography (floo-oh-RESS-ee-in / an-jee-OG-rah-fee)	**angi/o** = vessel **-graphy** = process of recording	Process of injecting a dye (fluorescein) to observe the movement of blood and detect lesions in the macular area of the retina. Used to determine if there is a detachment of the retina.
fluorescein staining (floo-oh-RESS-ee-in)		Application of dye eyedrops of a bright green fluorescent color used to look for corneal abrasions or ulcers.
keratometer kair-ah-TOM-eh-ter	**kerat/o** = cornea **-meter** = instrument to measure	An instrument used to measure the curvature of the cornea.
keratometry (kair-ah-TOM-eh-tree)	**kerat/o** = cornea **-metry** = process of measuring	Measurement of the curvature of the cornea using an instrument called a *keratometer.*
ophthalmoscope (off-THAL-moh-scope)	**ophthalm/o** = eye **-scope** = instrument for viewing	Instrument used to examine the inside of the eye through the pupil.
ophthalmoscopy (off-thal-MOSS-koh-pee)	**ophthalm/o** = eye **-scopy** = process of visually examining	Examination of the interior of the eyes using an instrument called an *ophthalmoscope* (see Figure 13.12 ■). The physician dilates the pupil in order to see the cornea, lens, and retina. Used to identify abnormalities in the blood vessels of the eye and some systemic diseases.

Diagnostic Procedures (continued)

Term	Word Parts	Definition
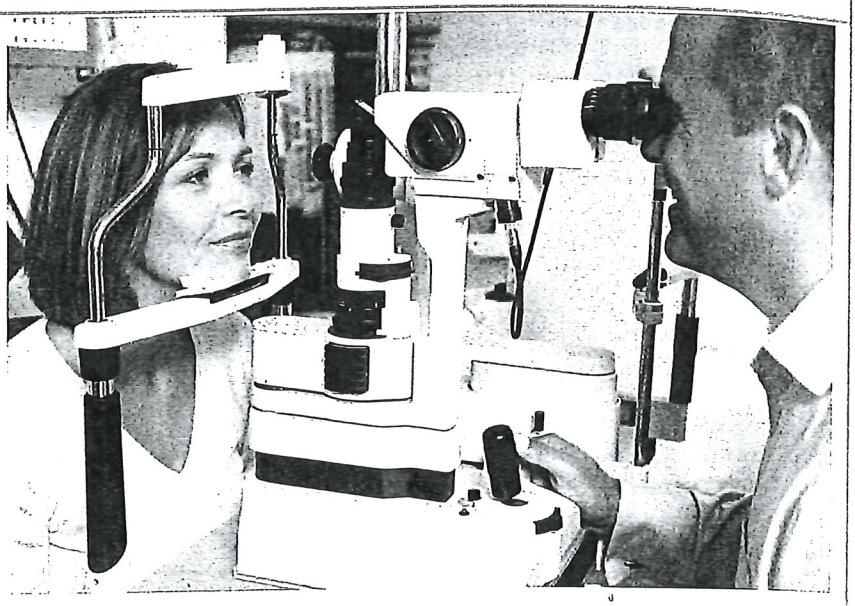 ■ **Figure 13.12** Examination of the interior of the eye using an ophthalmoscope. *(Monkey Business Images/Shutterstock)*		
optometer (op-TOM-eh-ter)	opt/o = vision -meter = instrument to measure	Instrument used to measure how well the eye is able to focus images clearly on the retina.
refractive error test (ree-FRAK-tiv)		Vision test for a defect in the ability of the eye to accurately focus the image that is hitting it. Refractive errors result in myopia and hyperopia.
slit lamp microscopy	micro- = small -scopy = process of visually examining	Examining the conjunctiva, cornea, iris, and lens of the eye.
Snellen chart (SNEL-en)		Chart used for testing distance vision named for Dutch ophthalmologist Herman Snellen. It contains letters of varying sizes and is administered from a distance of 20 feet. A person who can read at 20 feet what the average person can read at this distance is said to have 20/20 vision.
tonometry (tohn-OM-eh-tree)	ton/o = tone -metry = process of measuring	Measurement of the intraocular pressure of the eye using a *tonometer* to check for the condition of glaucoma. Generally part of a normal eye exam for adults.
visual acuity (VA) **test** (VIZH-oo-al / ah-KYOO-ih-tee)	-al = pertaining to	Measurement of the sharpness of a patient's vision. Usually, a Snellen chart is used for this test in which the patient identifies letters from a distance of 20 feet.

Therapeutic Procedures

Terms	Word Parts	Definition
Surgical Procedures		
blepharectomy (blef-ah-REK-toh-mee)	**blephar/o** = eyelid **-ectomy** = surgical removal	Surgical removal of all or part of the eyelid.
blepharoplasty (BLEF-ah-roh-plass-tee)	**blephar/o** = eyelid **-plasty** = surgical repair	Surgical repair of the eyelid. A common plastic surgery to correct blepharoptosis.
conjunctivoplasty (kon-junk-tih-VOH-plas-tee)	**conjunctiv/o** = conjunctiva **-plasty** = surgical repair	Surgical repair of the conjunctiva.
cryoextraction (cry-oh-eks-TRAK-shun)	**cry/o** = cold	Procedure in which cataract is lifted from the lens with an extremely cold probe.
cryoretinopexy (cry-oh-RET-ih-noh-pek-see)	**cry/o** = cold **retin/o** = retina **-pexy** = surgical fixation	Surgical fixation of the retina by using extreme cold.
enucleation (ee-new-klee-AY-shun)		Surgical removal of an eyeball.
iridectomy (ir-id-EK-toh-mee)	**irid/o** = iris **-ectomy** = surgical removal	Surgical removal of a small portion of the iris.
iridosclerotomy (ir-ih-doh-skleh-ROT-oh-mee)	**irid/o** = iris **scler/o** = sclera **-otomy** = cutting into	To cut into the iris and sclera.
keratoplasty (KAIR-ah-toh-plass-tee)	**kerat/o** = cornea **-plasty** = surgical repair	Surgical repair of the cornea is the simple translation of this term that is utilized to mean corneal transplant.
laser-assisted in situ keratomileusis (LASIK) (in-SIH-tyoo / kair-ah-toh-mih-LOO-sis)	**kerat/o** = cornea	Correction of myopia using laser surgery to remove corneal tissue.
laser photocoagulation (LAY-zer / foh-toh-koh-ag-yoo-LAY-shun)	**phot/o** = light	Use of a laser beam to destroy very small precise areas of the retina. May be used to treat retinal detachment or macular degeneration.

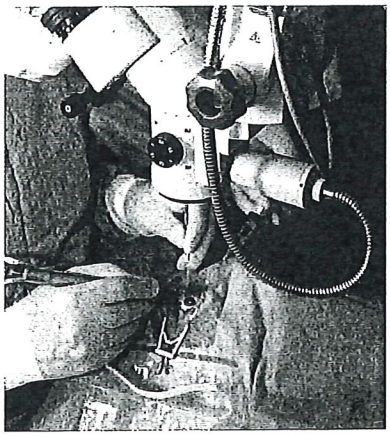

Figure 13.13 LASIK surgery uses a laser to reshape the cornea. *(mehmetcan/Shutterstock)*

Therapeutic Procedures (continued)

Terms	Word Parts	Definition
phacoemulsification (fak-oh-ee-mull-sih-fih-KAY-shun)	phac/o = lens	Use of high-frequency sound waves to emulsify (liquefy) a lens with a cataract, which is then aspirated (removed by suction) with a needle.
photorefractive keratectomy (PRK) (foh-toh-ree-FRAK-tiv / kair-ah-TEK-toh-mee)	phot/o = light kerat/o = cornea -ectomy = surgical removal	Use of a laser to reshape the cornea and correct errors of refraction.
prosthetic lens implant (pros-THET-ik)		Use of an artificial lens to replace the lens removed during cataract surgery.
radial keratotomy (RK) (RAY-dee-all / kair-ah-TOT-oh-mee)	-al = pertaining to kerat/o = cornea -otomy = cutting into	Spokelike incisions around the cornea that result in it becoming flatter. A surgical treatment for myopia.
retinopexy (ret-ih-noh-PEX-ee)	retin/o = retina -pexy = surgical fixation	Surgical fixation of the retina. One treatment for a detaching retina.
scleral buckling (SKLAIR-al)	scler/o = sclera -al = pertaining to	Placing a band of silicone around the outside of the sclera that stabilizes a detaching retina.
sclerotomy (skleh-ROT-oh-mee)	scler/o = sclera -otomy = cutting into	To cut into the sclera.
strabotomy (strah-BOT-oh-mee)	-otomy = cutting into	Incision into the eye muscles in order to correct strabismus.

Practice As You Go

D. Terminology Matching

Match each term to its definition.

1. _____ fluorescein staining
2. _____ ophthalmoscopy
3. _____ tonometry
4. _____ enucleation
5. _____ keratoplasty
6. _____ phacoemulsification

a. examining the interior of the eyeball
b. used to mean corneal transplant
c. liquefies a cataract
d. looks for corneal abrasions or ulcers
e. surgical removal of the eyeball
f. measures intraocular pressure

Pharmacology

Classification	Word Parts	Action	Examples
anesthetic ophthalmic solution (off-THAL-mik)	an- = without esthesi/o = sensation, feeling -tic = pertaining to ophthalm/o = eye -ic = pertaining to	Eyedrops for pain relief associated with eye infections, corneal abrasions, or surgery.	proparacain, Ak-Taine, Ocu-Caine; tetracaine, Opticaine, Pontocaine
antibiotic ophthalmic solution (off-THAL-mik)	anti- = against bi/o = life -tic = pertaining to ophthalm/o = eye -ic = pertaining to	Eyedrops for the treatment of bacterial eye infections.	erythromycin, Del-Mycin, Ilotycin Ophthalmic
antiglaucoma medications (an-tye-glau-KOH-mah)	anti- = against glauc/o = gray -oma = mass	Reduce intraocular pressure by lowering the amount of aqueous humor in the eyeball. May achieve this by either reducing the production of aqueous humor or increasing its outflow.	timolol, Betimol, Timoptic; acetazolamide, Ak-Zol, Dazamide; prostaglandin analogs, Lumigan, Xalatan
artificial tears		Medications, many of them over-the-counter, to treat dry eyes.	buffered isotonic solutions, Akwa Tears, Refresh Plus, Moisture Eyes
miotic drops (my-OT-ik)	mi/o = lessening -tic = pertaining to	Any substance that causes the pupil to constrict. These medications may also be used to treat glaucoma.	physostigmine, Eserine Sulfate, Isopto Eserine; carbachol, Carbastat, Miostat
mydriatic drops (mid-ree-AT-ik)	mydr/i = widening -atic = pertaining to	Any substance that causes the pupil to dilate by paralyzing the iris and/or ciliary body muscles. Particularly useful during eye examinations and eye surgery.	atropine sulfate, Atropine-Care Ophthalmic, Atropisol Ophthalmic
ophthalmic decongestants	ophthalm/o = eye -ic = pertaining to de- = without	Over-the-counter medications that constrict the arterioles of the eye and reduce redness and itching of the conjunctiva.	tetrahydrozoline, Visine, Murine

Abbreviations

ARMD	age-related macular degeneration	**EM**	emmetropia
Astigm	astigmatism	**EOM**	extraocular movement
c.gl.	correction with glasses	**ICCE**	intracapsular cataract extraction
D	diopter (lens strength)	**IOP**	intraocular pressure
DVA	distance visual acuity	**LASIK**	laser-assisted in situ keratomileusis
ECCE	extracapsular cataract extraction	**OD**	right eye
EENT	eye, ear, nose, and throat	**Ophth.**	ophthalmology

Abbreviations (continued)			
OS	left eye	**s.gl.**	without correction or glasses
OU	each eye/both eyes	**SMD**	senile macular degeneration
PERRLA	pupils equal, round, react to light and accommodation	**ST**	esotropia
PRK	photorefractive keratectomy	**VA**	visual acuity
REM	rapid eye movement	**VF**	visual field
RK	radial keratotomy	**XT**	exotropia

Med Term Tip

The abbreviations for right eye (OD) and left eye (OS) are easy to remember when we know their origins. OD stands for *oculus* (eye) *dexter* (right). OS has its origin in *oculus* (eye) *sinister* (left). At one time in history it was considered to be sinister if a person looked at another from only the left side. Hence the term *oculus sinister* means "left eye."

Practice As You Go

E. What's the Abbreviation?

1. pressure equalizing tube _____
2. emmetropia _____
3. exotropia _____
4. left eye _____
5. extraocular movement _____
6. visual acuity _____

Section II: The Ear at a Glance

Function

The ear contains the sensory receptors for hearing and equilibrium (balance).

Structures

Here are the primary structures that comprise the ear:

auricle
external ear
inner ear
middle ear

Word Parts

Here are the most common word parts (with their meanings) used to build ear terms. For a more comprehensive list, refer to the Terminology section of this chapter.

Combining Forms

acous/o	hearing	**labyrinth/o**	labyrinth (inner ear)
audi/o	hearing	**myring/o**	tympanic membrane
audit/o	hearing	**ot/o**	ear
aur/o	ear	**salping/o**	auditory tube (eustachian tube)
auricul/o	ear	**staped/o**	stapes
cerumin/o	cerumen	**tympan/o**	tympanic membrane
cochle/o	cochlea	**vestibul/o**	vestibule

Suffixes

-cusis	hearing
-otia	ear condition
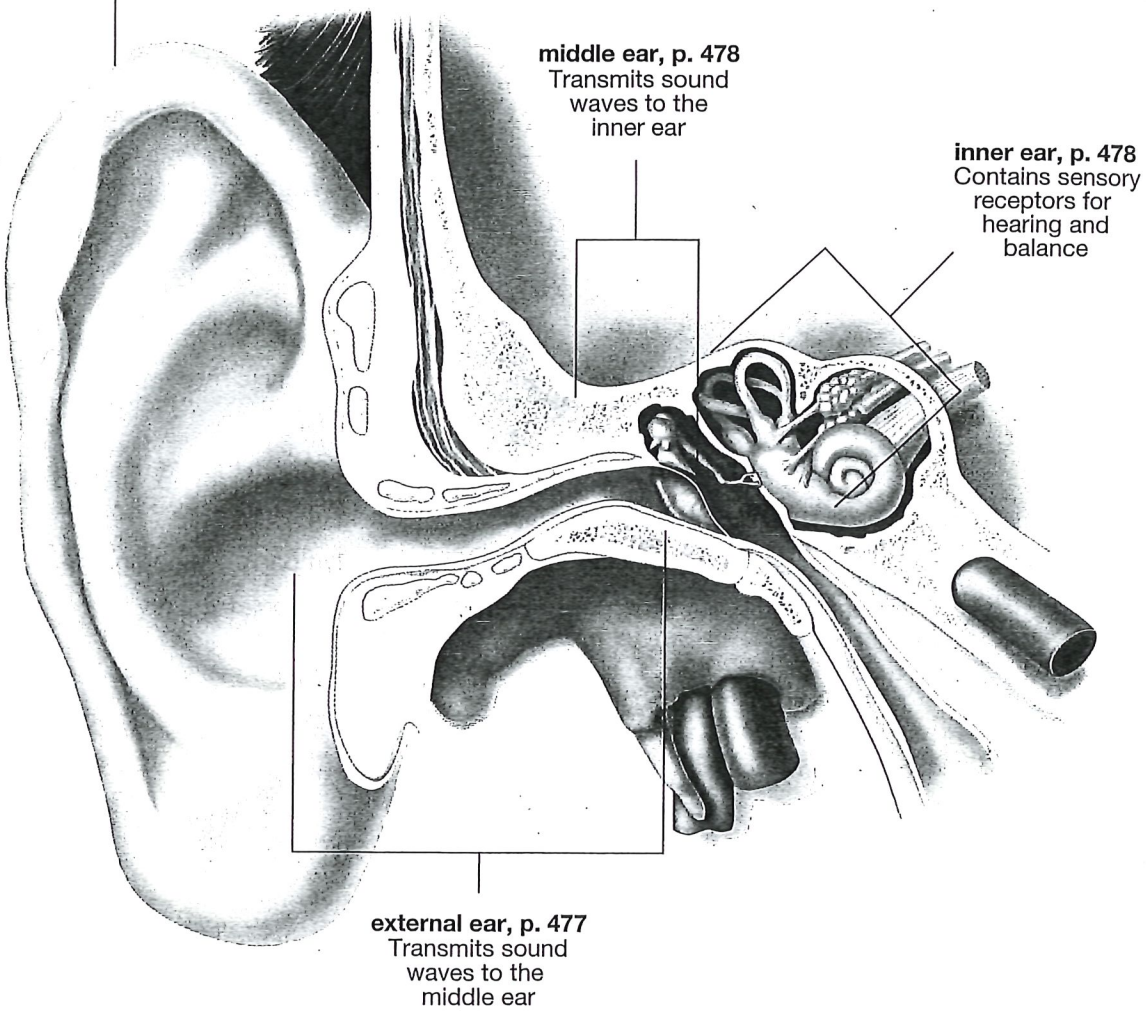
The Ear Illustrated